

Clinical Image*Open Access, Volume 3***Causeless? A new interrogation!****Jordi Robert Olalla***; **Uriarte Perez de Urabayen***Dexeus-Quironsalud University Hospital, Sabino Arana, 5-19, 08028 Barcelona, Spain.****Corresponding Author: Jordi Robert Olalla**Dexeus-Quironsalud University Hospital, Sabino
Arana, 5-19, 08028 Barcelona, Spain.

Tel: +34932530910;

Email: jordi.robert@quironsalud.es

Received: Dec 15, 2021

Accepted: Jan 21, 2022

Published: Jan 28, 2022

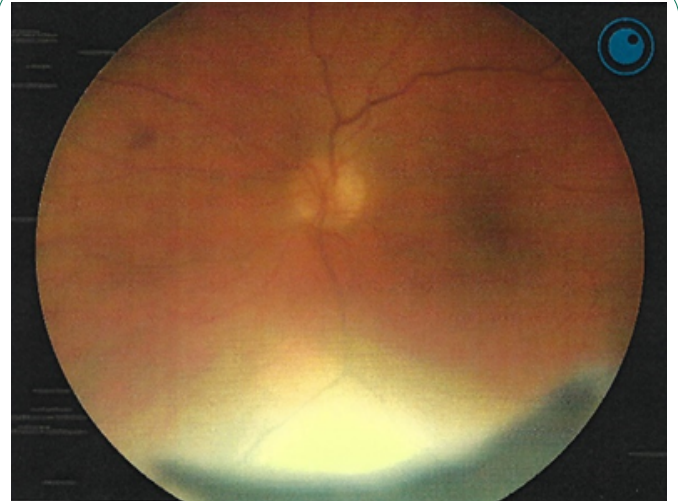
Archived: www.jcimcr.org

Copyright: © Olalla JR (2022).

DOI: www.doi.org/10.52768/2766-7820/1621

Description

A 77-year-old woman has sudden loss of vision in the lower left eye due to non-arteritic anterior ischemic optic neuritis. Seven days later, she presented sudden loss of vision in the right eye due to non-arteritic anterior ischemic optic neuritis. The usual causes have been ruled out. Blood pressure and diabetes are well controlled. Aspirin treatment begins after the first episode. The anamnesis stands out the abuse of nasal decongestants and nasal and ocular vasoconstrictors even after the first visual episode. It is an uncommon but described cause of anterior optic neuritis. Non-arteritic, bilateral, anterior ischemic optic neuritis due to nasal decongestant / vasoconstrictor abuse.

**Figure 1:** Right.

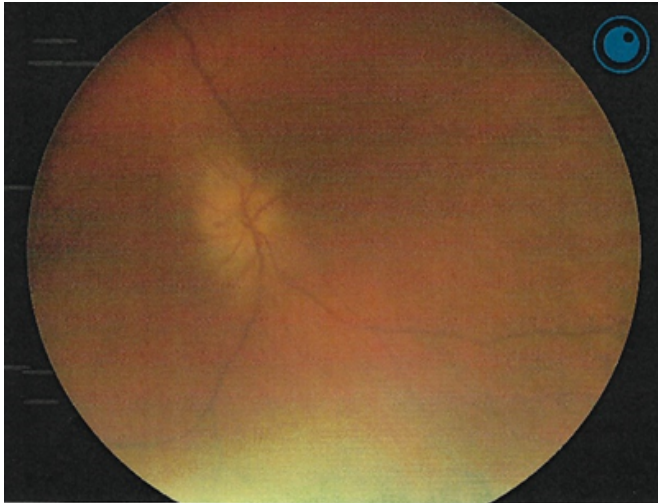


Figure 2: Left.