

Case Report*Open Access, Volume 3***A rare triad of fractures in the upper limb. Simultaneous fractures of the distal radius*****Corresponding Author: Mohamed Elgassim**

Department of Emergency Medicine, Hamad Medical Corporation, Doha, Qatar.

Email: muhamad.agadir@gmail.com

Received: May 16, 2022

Accepted: Jun 14, 2022

Published: Jun 21, 2022

Archived: www.jcimcr.org

Copyright: © Elgassim M (2022).

DOI: www.doi.org/10.52768/2766-7820/1901

Abstract

We're reporting a 35-year-old gentleman that presented with a rare combination of ipsilateral fracture of both proximal and distal ends of the radius associated with ulna styloid fracture due to a fall with outstretched hands. Thorough clinical examination of two adjacent joints (elbow and wrist) is critical in identifying such an unusual or rare combination of injuries. Appropriate management for such cases depends on the characteristics of the injury, such as fracture patterns, job, hand dominance, and age of the patient. The treatment should aim to preserve the radial head to avoid the possibility of proximal radial migration, particularly in young patients. Such a combination of injury implies complex injury and needs special consideration in deciding management plan. In this case, the proximal end of the radius and the ulna styloid fractures were treated conservatively. In contrast, the distal end of the radius was treated with open reduction internal fixation.

Introduction

Fractures affecting only the distal radius are common forearm injuries accounting for 14% of all extremity injuries and 17% of all adult fractures treated in emergency departments [1,2]. The simultaneous ipsilateral occurrences of both proximal and distal radius injuries are rare and rarely reported [1], and the concurring presence of the ulna styloid fracture has been unreported in the literature. The management of a simultaneous ipsilateral fracture proximal and distal ends of the radius depends on the stability of the fracture, the degree of displacement, fracture pattern, physical demand of the individual patient, and age. Currently, there are no best practice guidelines for the treatment of such fractures.

Background

We're reporting a case of a 35 y/o Asian gentleman from the subcontinent, with no known background comorbidities, no known past surgical procedures, or any previous symptoms in the affected limb.

Presentation

This adult male presented to our Emergency Department following a slip and fall on an outstretched hand from a standing height. The right upper limb took the majority of the impact of the fall. After the incident, the patient complained of a painful right wrist with minimal ability to move the wrist. He also complained of pain in his right elbow and could move it but with moderate limitations due to the pain. Upon physical examination, the patient's right elbow and wrist were moderately swollen. No apparent external deformity was seen. He had tenderness over the volar aspect of the wrist and tenderness over the lateral condylar area of the elbow. His range of motion was limited due to pain, and his neurovascular examination was intact. Plain radiographs of the right wrist revealed an intra-articular distal radius comminute fracture and a fracture of the ulnar styloid process, as shown in (Figure 1). Right Elbow plain radiograph showed fractures involving right radial head and neck regions, predominantly along an anterolateral aspect, as shown in (Figures 2 and 3). CT scans images are shown in (Figures 4-8).

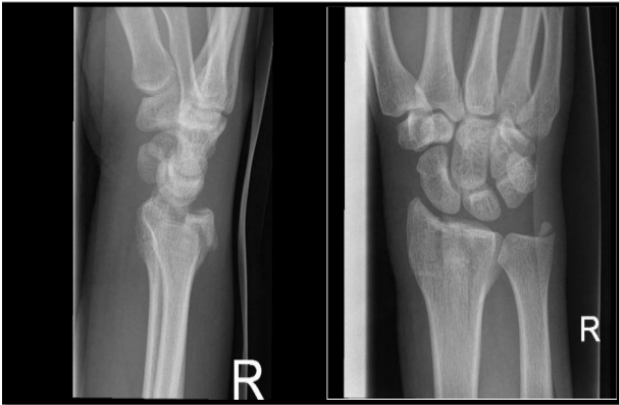

Figure 1: Comminuted distal radial intraarticular fracture with ulnar styloid process fracture.

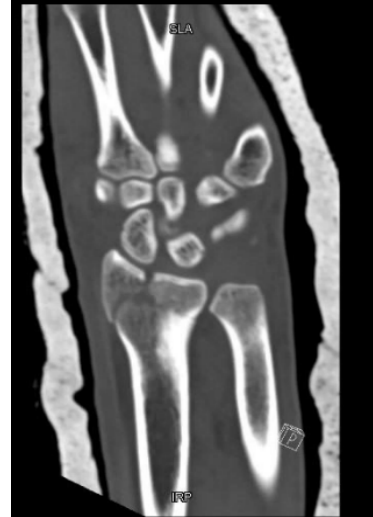

Figure 4: Displaced intra-articular distal radial fracture.

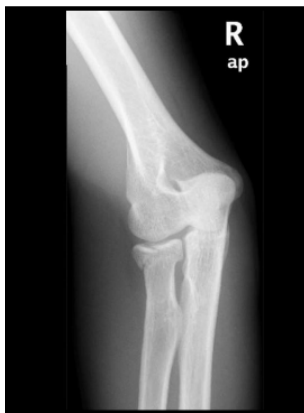

Figure 2: Radial head and neck fracture of the ipsilateral elbow.

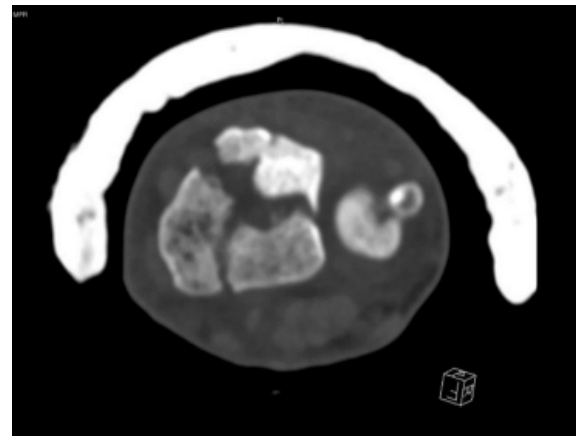


Figure 5: Cross-section of CT showing comminuted distal radial intra-articular fracture with the ulnar styloid avulsion fracture.

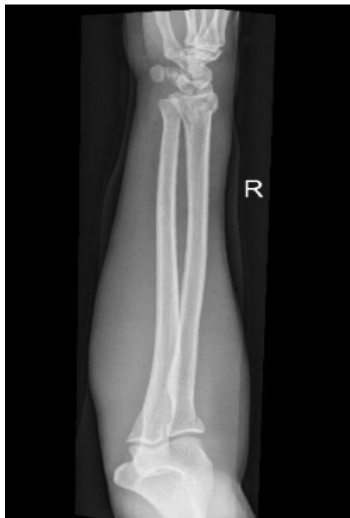

Figure 3: Impacted proximal radial neck and head fracture and distal intraarticular fracture of the radius and ulnar styloid avulsion fracture.

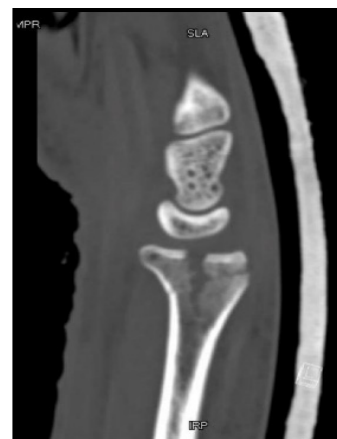

Figure 6: Lateral view of the radial intra-articular fracture.

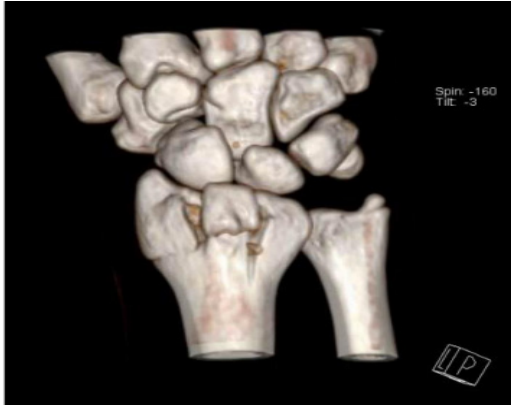


Figure 7: 3D Reconstructed CT wrist showing the fractures.

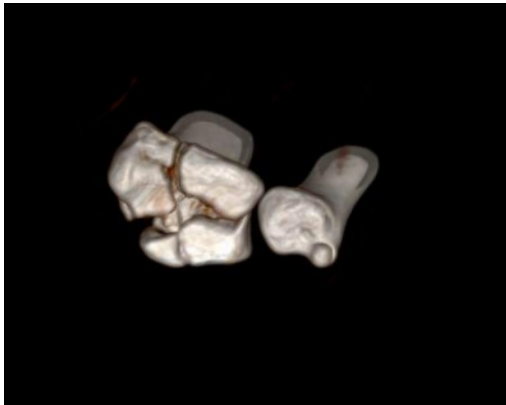

Figure 8: 3D Reconstructed CT of the distal radius and ulna.

Orthopaedics on-call assessed the patient, and he was admitted for open reduction and internal fixation of the distal radius fracture through plate and screws (Figure 9). The ulnar styloid and radial head fractures were treated conservatively.

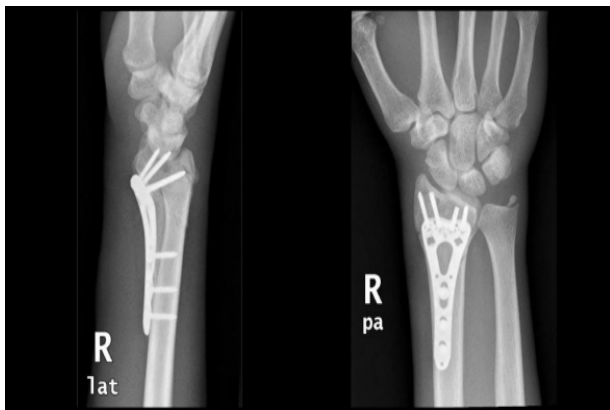

Figure 9: Plate and screws applied to the distal radius to stabilize the fracture.

Discussion

Distal radial fractures are common injuries among adults and children. In adults, distal radius fractures account for 17% of all fractures managed in the emergency departments [1]. Another aspect of radius fracture is the fracture of the proximal head/neck of the radius. However, the occurrence of ipsilateral distal and proximal heads are highly uncommon, and only a few cases have been reported [1].

The exact mechanism resulting in proximal and distal radius fracture is challenging to speculate. The mechanisms depend on the position of the forearm during the time of impact and the joint and whether the elbow was flexed or extended. Post-

erior tension forces have an essential contribution to the injury if the elbow is flexed. In which case, compression forces across the radiocapitellar joint are created if abduction thrust is present [2]. On the other hand, having the elbow is locked in extension creates compression forces across the radiocapitellar joint, leading to injury.

In addition to valgus and varus stresses, the forearm position is significant in determining fracture angulation. An increase in carrying angle may put the forearm in valgus stress and lead to proximal radius fracture and ulna, as noted by Henriksen [3]. Similarly, any varus strain might fracture the proximal radius or ulna [3]. The elbow sometimes experiences a temporary dislocation in these injuries [4]. The prognosis in the double injury is dictated by the trauma's energy and the skeletal maturity.

In the younger age group, these injury results from high-energy trauma with associated instability, comminution, and significant soft tissue injury. While in the older age group, the fracture complex could be due to low energy trauma with minimal displacement to the fracture and intact interosseous membrane, therefore, having a better prognosis. In the pediatric group, the fracture pattern is complicated by premature epiphyseal fusion and avascular necrosis of radial epiphysis [5].

Another similar injury pattern of double injuries is the Essex Lopresti fracture and Monteggia fracture. There's a radial head fracture in Essex Lopresti injury, with associated rupture of interosseous membrane and dislocation of the distal radioulnar joint resulting in forearm instability [6,7].

Unlike the Essex Lopresti injury, in Monteggia, the fracture is in the ulna, not the radius, and there's a dislocation of the radial head; and according to Bado classification, there are four subtypes of Monteggia fracture. The most severe type is Monteggia fracture type IV, in which there's an anterior dislocation and fracture involving both the radius and the ulnar shaft [8].

Therefore, Patients with an increased carrying capacity present with a distal radial fracture should be subjected to a systemic elbow examination. Radiography of the elbow should be done in all cases of distal radius fracture in which there is suspicion of the presence of concomitant elbow trauma. In our patient, plain radiography demonstrates an intra-articular distal radius comminute fracture accompanied by a fracture of the ulnar styloid process (Figure 1). Radiography of the right elbow was also showed fractures involving the right radial neck and head regions, mainly along an anterolateral aspect (Figures 2,3). CT scans images shown in figures 4-9. The most appropriate modality of treatment of such complex triple injury fractures relies on the characteristics of the fractures, like the stability of the fracture, the degree of displacement, and the fracture pattern, physical demands, and the age of the patient [2].

Our patient's radial head fracture was managed conservatively. The radial head articular surface should be preserved either by surgical or non-operative conservative methods to prevent proximal radial migration. Young people with these complex injuries are at risk of proximal migration of radius due to associated soft injury and inter-osseous membrane injury.

There are no best practical guidelines for the treatment of ipsilateral proximal and distal fracture ends of radius. Il-Jung Park [10] study provided recommendations for treating a similar condition. Their study stated that the radial length should be taken into consideration. This is because of the risk of radial shortening in a proximal radial fracture which could be more

severe when accompanied by distal radius fracture [9]. In our patient, an open reduction internal fixation was done to the right distal radius. Il-Jung Park [10] stated that fixation of the distal radius allows for the restoration of radial length and prevents instability or radiocapitellar overstuffing. The study recommended operation on the wrist first, followed by performing the radial head replacement. Consideration towards the elbow and the wrist should be taken in surgery and postoperative care as complications such as fracture collapse or metal failure may arise due to early rehabilitation. At the same time, prolonged immobilization may cause arthritic changes or joint contractures [10]. Patients may experience arthritic changes or joint contracture due to long periods of immobilization [11]. Hence, good clinical outcomes are possible with good reduction and anatomical alignment, maintaining or restoring normal intra-articular surface promoting bony union and healing, and guided effective rehabilitation methods. Patients should have a full explanation of the prognosis and outcome.

References

1. Anil Agarwal. Ipsilateral fracture of distal and proximal ends of the radius: Does this injury pattern deserve special attention? *Eur J Orthop Surg Traumatol.* 2007; 17: 181–187.
2. El Kadi, Khalid Ibn, et al. Simultaneous ipsilateral fractures of distal and proximal ends of the radius. *The Pan African medical journal.* 2017; 27: 98.
3. Henrikson B. Isolated fracture of the proximal end of the radius in children. *Acta Orthop Scand.* 1969; 40: 246–260.
4. Newman JH. Displaced radial neck fractures in children. *Injury.* 1977; 9: 114–121.
5. Jones ERW, Esah M. Displaced fractures of the neck of radius in children. *J Bone Joint Surg.* 1971; 53: 429–439.
6. Dodds SD, Yeh PC, Slade JF, III Essex-lopresti injuries. *Hand Clin.* 2008; 24: 125–137.
7. Essex Lopresti P. Fractures of the radial head with distal radio-ulnar dislocation; report of two cases. *J Bone Joint Surg (Br)* 1951; 33: 244–247.
8. Beutel, Bryan G. Monteggia fractures in pediatric and adult populations. *Orthopedics.* 2012; 35: 138-144.
9. Duckworth AD, Watson BS, Will EM, et al. Radial shortening following a fracture of the proximal radius. *Acta Orthop.* 2011; 82: 356–359.
10. Park, Il-Jung, et al. Simultaneous ipsilateral distal radius and radial head fractures: Two case reports of radius bipolar fracture. *Medicine.* 2021; 100: e24036.
11. Maripuri SN, Debnath UK, Rao P, et al. Simple elbow dislocation among adults: A comparative study of two different methods of treatment. *Injury.* 2007; 38: 1254–1258.