

Clinical Image

Open Access, Volume 4

Colo-colic intussusception due to left colic tumor: A rare cause in adults

***Corresponding Author: Trabelsi Mehdi**

Charles Nicolle hospital, Tunisia.

Tel: +21-690064402;

Email: drmehdi.trabelsi@gmail.com

Received: Jan 11, 2023

Accepted: Jan 27, 2023

Published: Feb 03, 2023

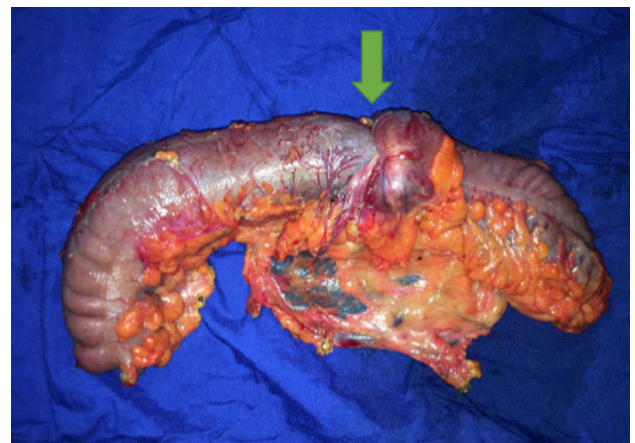
Archived: www.jcimcr.org

Copyright: © Trabelsimehdi (2023).

DOI: www.doi.org/10.52768/2766-7820/2271

Description

Intussusception in adults is quite rare. Among the leading causes, tumor comes first. A 49-year-old male admitted for acute bowel obstruction due to left colo-colic intussusception. The patient underwent laparotomy. Intraoperatively: there was a hard mass palpated within the intussuscepted bowel. We performed a left colectomy with double barrel colostomy. Because of the more common idiopathic intussusception found in children, only reduction may be efficient in this age group. However intussusception in adults remains a surgical disease.



Figure

Citation: Mehdi T. Colo-colic intussusception due to left colic tumor: A rare cause in adults. J Clin Images Med Case Rep. 2023; 4(2): 2271.