

Clinical Image

Open Access, Volume 4

Lipoma arborescens: An uncommon diagnosis for swelling knee**Yosra Bouattour***; Ichrak Mnif; Faten Frikha; Zouhir Bahloul

Internal Medicine Department, Hedi Chaker Hospital, Sfax Tunisia.

***Corresponding Author: Yosra Bouattour**

Internal Medicine Department, Hedi Chaker Hospital, Sfax Tunisia.

Email: yosrabouattour.sfax@gmail.com

Abstract

Lipoma arborescens is an extremely rare and benign condition affecting joints synovial tissue. It should be suspected in patients with very slow mono-articular swelling.

Received: Feb 09, 2023

Accepted: Apr 07, 2023

Published: Apr 14, 2023

Archived: www.jcimcr.org

Copyright: © Bouattour Y (2023).

DOI: www.doi.org/10.52768/2766-7820/2371

Description

A 30-year-old woman with no prior medical history reported left knee pain and swelling evolving for 4 years. The swelling had progressively worsened over the past 4 months, becoming resistant to analgesics and non-steroidal anti-inflammatory drugs. Physical examination showed only a positive patellar shock on the left without local inflammatory signs. Biological data were within normal range particularly, phosphocalcic and uricemia tests. The conventional knee radiograph was normal. Joint fluid was sterile on puncture, with a predominance of neutrophil cells. There were no crystals. Magnetic Resonance Imaging (MRI) was performed, showing multiple hypointense T1 formations that are FAT/SAT enhanced in the quadriceps bursa. These formations take up contrast after gadolinium injection, with a heterogeneous bone framework, as well as a large intra-articular effusion. A biopsy was indicated and microscopic examination confirmed that it was a lipoma arborescens of the knee with foci of abscessation.

The patient was treated by a subtotal removal of the intra-articular tumor. Two years later, she reconsulted for relapse of pain and swelling of the left knee related to a gonarthrosis.

Lipoma arborescens is an uncommon benign type of lesion that may occur in the synovium lining of joints or bursae. It is characterized by villous, non-destructive lipomatous proliferation of synovial tissue and mainly affects the suprapatellar pouch of the knee [1]. It occurs at any age with no gender predominance. X-ray shows non-specific findings (Figure 1). MRI with fat saturation sequences features includes joint effusion, arborescent or frond-like synovial masses. Only histological investigations provide a definitive diagnosis and classification of this nonmalignant soft tissue tumor. Surgical excision should be considered in case of manifest pain or movement restriction. Relapses following synovectomy have not been reported [2]. On the other hand, few authors incriminated lipoma arborescens in the early development of arthrosis.

Citation: Bouattour Y, Mnif I, Frikha F, Bahloul Z. Lipoma arborescens: An uncommon diagnosis for swelling knee. J Clin Images Med Case Rep. 2023; 4(4): 2371.

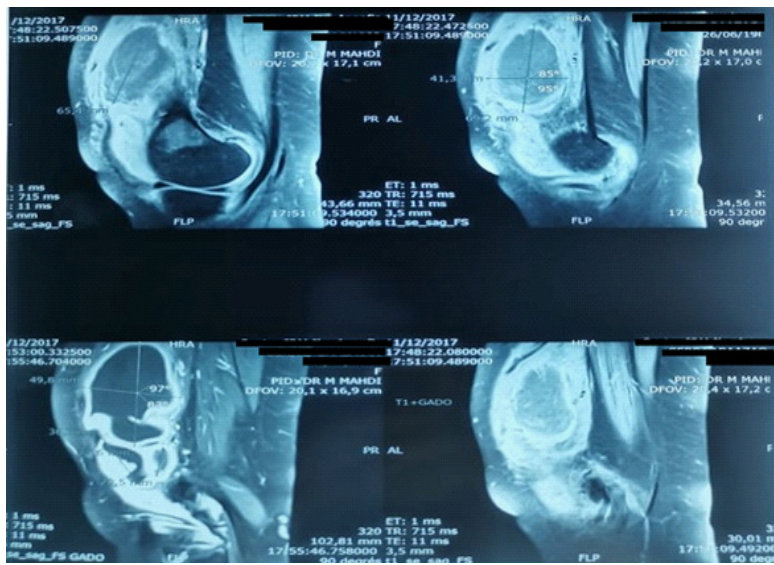


Figure 1: