

Clinical Image

Open Access, Volume 4

Large posterior fossa arachnoid cyst

Halfi Mohamed Ismail*; Lrhorfi Najlae; Allali Nazik; Chat Latifa

Department of Radiology, Children's Hospital, Ibn Sina University Hospital Center, Rabat, Morocco.

*Corresponding Author: **Halfi Mohamed Ismail**

Department of Radiology, Children's Hospital, Ibn Sina University Hospital Center, Rabat, Morocco.

Email: ismail.m.halfi@gmail.com

Received: Apr 18, 2023

Accepted: May 05, 2023

Published: May 12, 2023

Archived: www.jcimcr.org

Copyright: © Ismail HM (2023).

DOI: www.doi.org/10.52768/2766-7820/2411

Clinical image description

A 4-year-old male child presented to the emergency department after a first seizure. His family report the recently had frequent headaches and consciousness disorders. Magnetic resonance imaging of the brain revealed an arachnoid cyst, measuring 5.0 cm by 9.0 cm by 8.2 cm, lateralized on the left. The cyst is responsible for an elevation of the tentorium of the cerebellum, a mass effect on: fourth ventricle, aqueduct of Sylvius and midbrain diencephalic structures and causing a moderate upstream responsible for upstream protected hydrocephalus with no sign of trans-ependymal resorption. The left cerebellar hemisphere and the vermis were shifted to the right of midline by 7 mm. Arachnoid cysts are congenital malformations containing cerebrospinal fluid. Usually, there are asymptomatic and are considered benign incidental finding on imaging. In some case, such as ours, the cyst can take an immense size becoming symptomatic due to mass effect. Although fenestration through craniotomy is the most frequently adopted first-line treatment, a more conservative approach was decided in our case. The patient underwent a microscopic fenestration via a craniotomy in order to release the cyst compression and restore the intracranial pressure. Post-operative imaging showed a significant downsize of the cyst. The symptoms have subsidized and anti-epileptic therapy has been prescribed using preventive doses to manage eventual seizures.

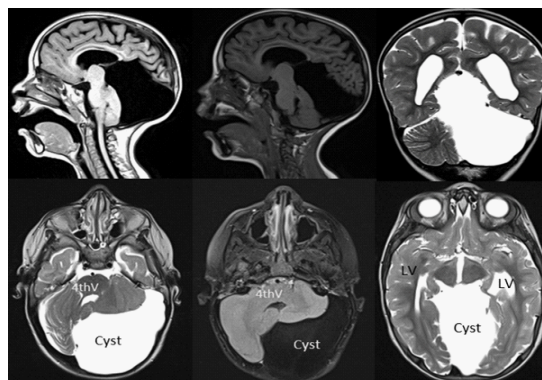


Figure 1:

References

1. Large Arachnoid Cyst. de Longpre J. N Engl J Med. 2017; 376: 2265.
2. An infantile case of posterior fossa arachnoid cyst presenting with marked engorgement of contralateral supraorbital vein. Makino K, Tsutsumi S, Takaki Y, Nonaka S, Okura H, Ishii H. Radiol Case Rep. 2021; 16: 3680-3684.

Citation: Ismail HM, Najlae L, Nazik A, Latifa C. Large posterior fossa arachnoid cyst. J Clin Images Med Case Rep. 2023; 4(5): 2411.