

## Clinical Image

Open Access, Volume 4

# Illustration of skin diseases in the unani clinical research OPDs

Humaira Bano<sup>1\*</sup>; Nikhat Sheikh<sup>2</sup>; Sidra<sup>3</sup>

<sup>1</sup>Colocation Research Centre, RRIUM, Mumbai, J.J. Hospital, Byculla, Mumbai-400008, India.

<sup>2</sup>Regional Research Institute of Unani Medicine, Kharghar, Navi Mumbai, India.

<sup>3</sup>PG Scholar NIUM, Bangalore, India.

**\*Corresponding Author: Humaira Bano**

Colocation Research Centre, RRIUM, Mumbai, J.J.

Hospital, Byculla, Mumbai-400008, India.

Email: banu786.mau@gmail.com

### Abstract

These are the nine images taken in Unani research OPDs related to skin disease as Unani System of medicine has significant result in skin and cosmetics fields. Patients who had taken treatment from the specialist did not cure moved to Unani treatment. Here the purpose is only to present the cases of skin diseases with special peculiarities met in the Unani Research Centre.

**Keywords:** Skin disease; Unani system of medicine; Case reports.

Received: Jun 15, 2023

Accepted: Jun 28, 2023

Published: Jul 05, 2023

Archived: www.jcimcr.org

Copyright: © Bano H (2023).

DOI: www.doi.org/10.52768/2766-7820/2486

### Introduction

Unani System of Medicine is one of the ancient systems of Medicine, in a historical course, the embranchment of sciences have flourished from the Greek medical knowledge. Now, India is the largest land in which the Unani system of Medicine is still growing with glorious practices of advanced research and provision of health facilities for curing various complex, untreatable diseases.

The Unani system of Medicine presents Skin diseases in the inclusion of skin, hair and nails in two folds meanings.

I. Diseased condition and treatment.

2. Maintenance and enhancement of the beauty of skin, hair and Nails.

Skin is an interface of the Human body to the environment, In Unani literature has presented the finest definition of the skin "Skin of the human is made up weaker and softer than other animals' because its primary aim to beautify the human body and secondary is to protect the body from external factors and remove out the metabolized wastages in favour of internal organ which move toward the skin to excrete out in the mean of strengthen it" [1].

After interrogations, and examination of the disease, the utmost thing for the Unani physician is to understand which humour is involved being the reason for this condition; a large field is always open and invites the physician to measure the parameter in the direction of correct diagnosis and move on treatment. Importantly, location, size, shape, colour, severity and symptoms are the primary parameters to know the temperaments of patient. Additionally, previous disease if any, dietary habit, addiction, lifestyle and other circumstances necessary to document in this favour. All diseases of the skin always is an inflammatory condition [1,2].

### Images descriptions

**Image 1:** A 12 year old boy has a Unique presentation of ringworm infection in a highly marked outline of a large ring-shaped that covers from chest to abdomen. In the Unani system of Medicine, this peculiarity denotes the word 'Quba' caused by burnt black bile when accumulated within the skin [5,6].

**Image 2:** A 78-year-old female patient with a complaint of excessive secretion from eyes with deposition of plaques on the face with intense itching, hot flushing and red eruption on the other part of the body with disease of systemic sclerosis.

**Images 3 & 4:** A 50 year old female patient with colossal fun-

gal infection in her feet and hands has intense burning pain, itching and exfoliated skin as carded cotton with an atrophied appearance and fissuring in skin. In Unani system of medicine it is known as takarruj (Fungus) due to enough insufficient temperature and nutrition reached, or continue wetted feet and hands [1,5,6].

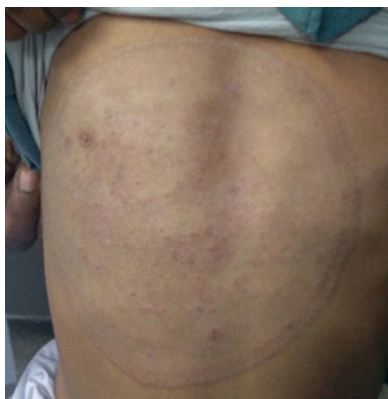
**Image 5** is taken of a five year old child who was having patches, extreme dryness in his head, in Unani system of medicine it is called *Quba-e-Ras* or *safa-e-Yabusu* (Tinea capitis) [4]. In this disease black bile in excess mixed in blood reached to scalp to evacuating out but settled in the skin as patches or homogeneous.

**Image 6** shows dense and severely erupted warts in the beard area of a 24-year-old man who had an estranged history of one wart was there. He extracted-out himself manually, but after that, it got massive and spread over the region. He had no option except laser surgery, but the patient was worried about not security to be a cure or significant impact in the future.

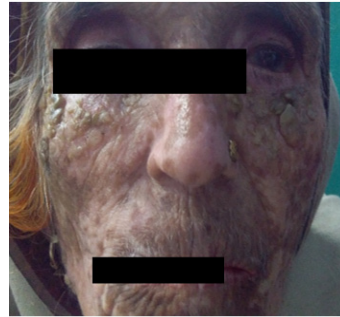**Image 7:** 46-year-old male patient with severe itch with enormous eruption over the arms already had been diagnosed with lichen planus as had eruptions with itching and dry lustre of skin and dirty appearance of the arm, thus patients got a lot of physical difficulties and poor quality of life and social detachment. In the Unani system of medicine, it is called *Hikka Yabis* caused by thick sticky phlegm with black bile overwhelming in the skin due to insufficient evacuation of the wastage [3,6].

**Image 8** is a 55-year-old male patient with patchy eruption with severe itch over the ear and dryness shredded off the skin from the head with loss of hair also. The patient was diagnosed with psoriasis. In Unani medicine is called *Da-ul-sadaf/ Taqashshur-e-jild* caused by impairment of *Quwat-e-mughairah* [4,5].

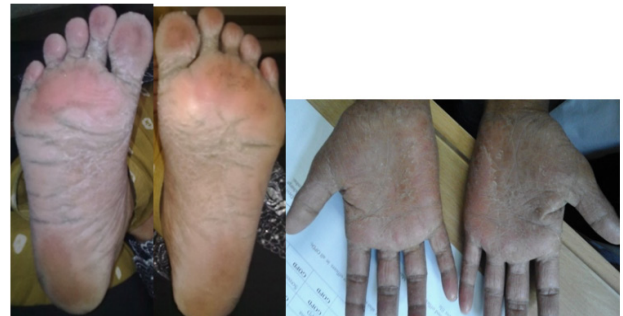**Image 9:** This is a 27 years old man, who came to seek treatment for a severe, enormous pustulous eruption with fever and painful condition and stress in bewildering of monkeypox during the pandemic. He had severe pus formation in big-sized pustules up to 8 mm on the back shoulder of both arms. He has experienced intense itching and eruption continually occurred with new pustules.



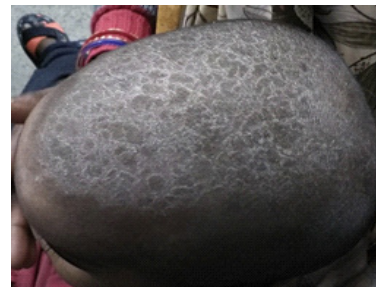**Figure 1:** Tinea infection in 12 years old.



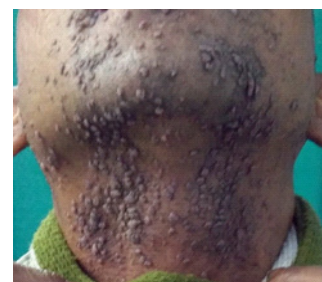**Figure 2:** Psoriatic plaques on the face of 78 year old female.



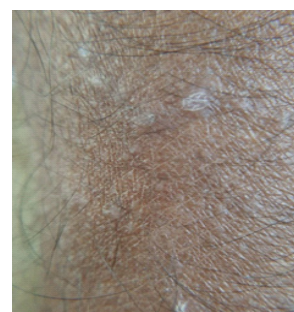**Figures 3 & 4:** Fungal infection in hands and feet- 50 year old female patient.



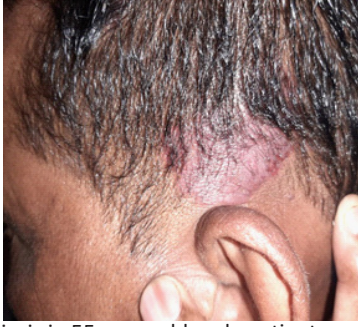**Figure 5:** Tinea capitis in 5 years old child Image.



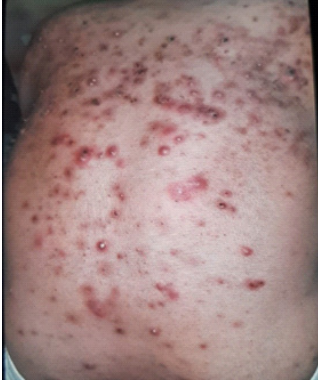**Figure 6:** Raer case of warts on beard area in young man.



**Figure 7:** Chronic itching and eruption on arms.



**Figure 8:** Psoriasis in 55 years old male patient.



**Figure 9:** Acute pustulosis (After viral fever) in 27 years old man.

## Declarations

**Originality and content:** All images are original, taken after content off the patients.

**Sponsorship financial support:** There is no sponsorship and finance from any orgainzation or agency.

**Conflict of intrest:** There is no conflict of interest.

## References

1. Ibn Zuhr, Abu Mrawan Abdul Malik, Kitab al-taiser. Central Council for Research In Unani Medicine Ministry of Health and family welfare Govt. of India, New Delhi.1986; 94-193.
2. Jūrjānī Mohammad Ismail, Tarjuma Zakheera-e-Khwarzam Shahi. Urdu. Munshi Naval Kishore. Lucknow. 1903; 19,30,35,37,42.
3. Ibn-Al-Quff, Aminud-daula Abul-furj ibnul quff Al-masihi. Kitab-Al-Umdah fil jarahat Urdu Central Council Research in Unani Medicine Ministry of Health and Family welfare Govt. of India New Delhi. 1896; 102. Urdu.
4. Tabri, Abūl Hasan Ahmad Bin Muhammad. Al-MūālījatBūqratīya Urdu CCRUM, New Delhi. 1997; 180,207.
5. Ibn Sina, Abu Ali Hussain bin Abdullah. Alqanoon fil Tib. Urdu by Gulam Hasnain Kanturi. Munshi Naval Kishore Lucknow.1929; 360-361,367-369.
6. Arzani, Hakeem Muhammad. Tibb-e-Akbar. Urdu by Hakeem Muhammad Haussain. Idara Kitab-al-shifa Daryaganj Delhi. 1903; 698,738-739.