

**Clinical Image***Open Access, Volume 4***Single live 8 weeks ectopic pregnancy in rudimentary horn of unicornuate uterus****\*Corresponding Author: Smritika Mohanrao Taware**

Dr. D. Y. Patil College of Ayurved &amp; Research Centre, Pimpri, Pune, Maharashtra, India.

Tel: 09850967067

Email: bhonsalesmritika@gmail.com

Received: Nov 22, 2023

Accepted: Dec 20, 2023

Published: Dec 27, 2023

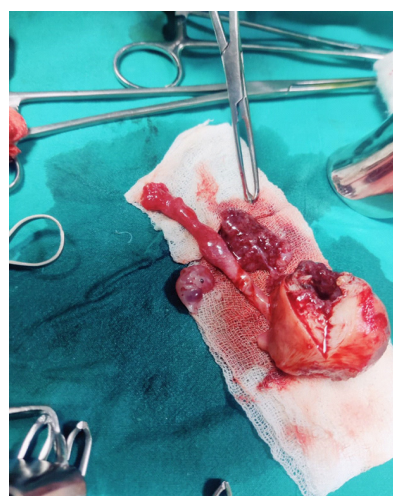
Archived: www.jcimcr.org

Copyright: © Taware SM (2023).

DOI: www.doi.org/10.52768/2766-7820/2759

**Description**

Female aged 26 years detected as single live pregnancy of 8 weeks in right tube. She was diagnosed as right tubal ectopic and referred for confirmation of diagnosis to another Sonography centre as pregnancy grew up to 8 weeks with normal foetal heart sound and if it was tubal would have ruptured earlier. Now the diagnosis was Unicornuate uterus with pregnancy in Rudimentary horn. She was posted for Laparotomy for Rudimentary horn Resection. Surgery was uneventful and patient got discharged with no complaints and further instructions.

**Citation:** Taware SM. Single live 8 weeks ectopic pregnancy in rudimentary horn of unicornuate uterus. J Clin Images Med Case Rep. 2023; 4(12): 2759.