

Case Series

Open Access, Volume 5

Inflammatory granulomatous mastitis (IGM), a precursor of cancer or a trap for misdiagnosis, a case report study

Mohammad Esmail Akbari*; Maryam Omrani Hashemi; Najmeh Bagherhosseini; Fereshteh Abbasvandi; Morteza Yousefi Darani; Mohammad Seraj; Mahdis Bayat; Afsaneh Sadat Makeh

Cancer Research Center, Shahid Beheshti University of Medical Sciences, Tehran, Iran.

*Corresponding Author: Akbari ME

Cancer Research Center, Shohadaye Tajrish Hospital, Shahid Beheshti University of Medical Sciences, Tehran, Iran.

Tel: +98-21-22748001/2;

Email: Profmeakbari@gmail.com

Received: Dec 19, 2023

Accepted: Jan 10, 2024

Published: Jan 17, 2024

Archived: www.jcimcr.org

Copyright: © Akbari ME (2024).

DOI: www.doi.org/10.52768/2766-7820/2803

Abstract

This case report delves into the fascinating journey from Idiopathic Granulomatous Mastitis (IGM) to malignancy. Although IGM is generally considered a benign breast condition, it can often present symptoms that resemble more serious conditions like cancer leading to diagnostic confusion. By examining these instances of misdiagnosis, we aim to contribute to the discussion surrounding IGM and its potential links to cancer. The report discusses two clinical cases where patients with a history of IGM went on to develop malignancies—an exceedingly rare occurrence akin to finding a needle in a haystack. The first case involves a 37-year woman initially diagnosed with IGM, who later presented an enlarged mass that was ultimately confirmed as high-grade ductal carcinoma in situ. The second case is equally complex and unusual—a 40-year-old woman diagnosed with IGM and a developed bloody nipple discharge during her treatment leading to the discovery of invasive ductal carcinoma. These cases highlight the debate regarding the role of chronic inflammation in triggering cancerous transformations, a connection that has yet to be definitively proven or disproven for breast tissue. As such this report aims to stimulate research into this rare but scientifically intriguing association, between IGM and malignancy. These thought provoking cases pose questions about current practices in clinical, radiological and pathological approaches. They also drive advancements in our understanding of the causes of breast cancer in relation, to idiopathic granulomatous mastitis.

Keywords: Idiopathic granulomatous mastitis; Ductal carcinoma in situ; Invasive ductal carcinoma; Chronic inflammation; Breast cancer.

Introduction

Idiopathic Granulomatous Mastitis (IGM) is an uncommon non-neoplastic breast disease [1]. It usually strikes in the third or fourth decade of life [2]. IGM's causes are not completely understood; The disease has been linked to a wide range of probable causes, including infectious agents, autoimmune processes, hormonal abnormalities, hyperprolactinemia, alpha 1 antitrypsin deficiency, IgG4-related disease, pregnancy-birth

and lactation, cigarette smoking, and even ethnic factors [3]. It can cause symptoms and findings such as a painful mass, skin distraction, breast inflammation, irritation, orange-peel sign, sinus secretion, and lymph node development [3]. Imaging and clinical Features mimic cancer presentation. As a consequence, tissue diagnosis via core biopsy is essential procedure to confirm disease [3]. IGM treatment is not yet standardized, but it includes surgical and non-surgical options such as antibiotics, steroidal and nonsteroidal anti-inflammatory drugs, and im-

munosuppressive drugs [3]. The primary goal of therapy is to alleviate symptoms. Granulomatous mastitis typically resolves on its own after 1-2 years if left untreated [4]. Epidemiological and experimental evidence point to a link between inflammation and cancer [5].

Case presentations

Case 1

A woman aged 37 years old with history of a mass (3×3 cm) in upper outer quadrant of left breast that was diagnosed with idiopathic granulomatous mastitis referred to the breast clinic. Her illness began in February 2018 when she noticed a lump in her left breast and IGM was diagnosed for her by core needle biopsy and received no medical treatment [Figure 1]. However, after 18 months in September 2019 the patient noticed an enlargement in the mass and bloody discharge of nipple appeared. So, a sono-guided biopsy was performed and malignancy was confirmed as high-grade Ductal Carcinoma Insitu (DCIS), (Figure 2) and management of DCIS was done.

Case 2

A female patient aged 40 years old presented with a 3-month history of a painful right breast mass and no family history of breast cancer. A 5 cm lump in the right breast upper outer por-

tion, erythematic overlying skin, a single purulent discharging orifice, and no lymphadenopathy were found in physical examination. Ultrasound reported multiloculated fluid collection suggestive of small abscesses (BIRADS: 4B). After a core needle biopsy revealed FCC with active chronic inflammation (Figure 3), she was diagnosed with IGM and treated non-surgically. In the third month of treatment, the patient had a complain of bloody nipple discharge. Micro calcification in the central zone was discovered by mammography, and a core biopsy reported invasive ductal carcinoma (Figure 4), making the patient a surgical candidate.

Discussion

IGM is a benign and relatively uncommon disorder that can be difficult to distinguish from breast carcinoma [7]. The association of granulomatous mastitis and breast carcinoma is extremely rare [3]. At the time of publication, only a few other reports had suggested the possibility of a link between IGM and malignancy [8]. These reports have been extracted among 270 IGM cases through our 15 years registered data. Numerous stages of carcinogenesis, such as cellular transformation, promotion and proliferation, invasion and angiogenesis as well as metastasis and survival, have been linked to chronic inflammation [5]. The hypothesis that persistent inflammation causes cancer is well documented [7], and it was first described by

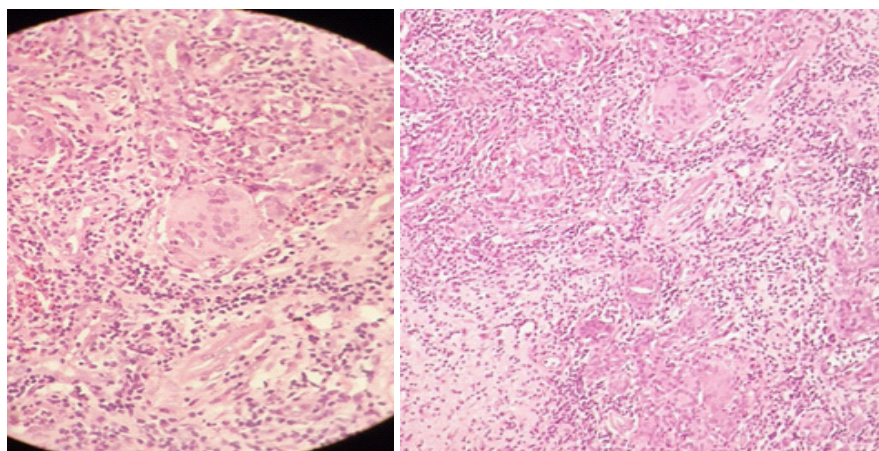


Figure 1: Granulomatous inflammation centered on breast lobules.

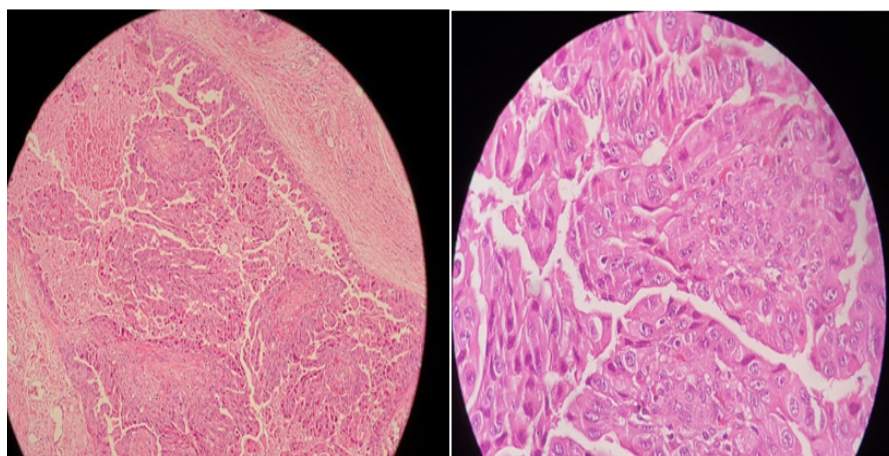


Figure 2: High-grade Ductal Intra-epithelial Neoplasia, Solid and Comedo types.

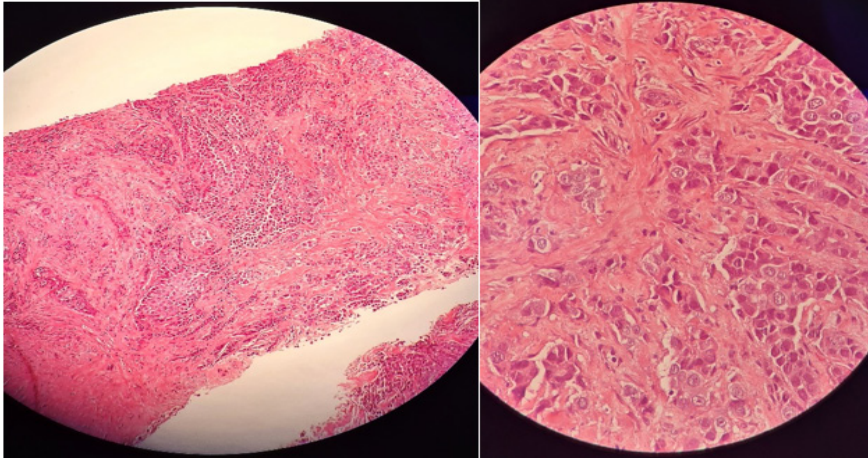


Figure 4: Invasive ductal carcinoma, NOS.

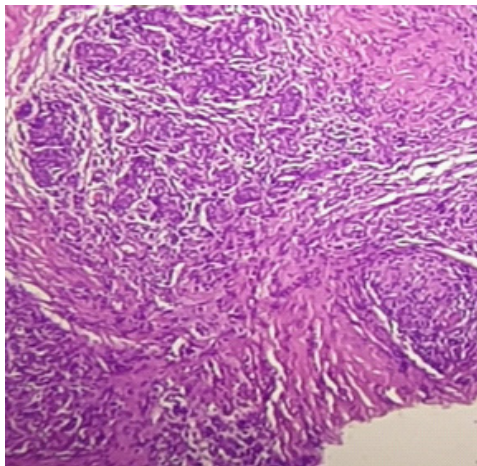


Figure 3: Mixed inflammatory cell infiltration with many histiocytes.

Rudolf Virchow in 1863, after discovering the presence of leukocytes in neoplastic tissues [6]. Unlike in some other organs, where infection or irritation has been significantly associated to the formation of malignant tumors, this has not been established in breast tissue [8]. Despite the fact that women with a history of mastitis appear to have a slightly increased overall risk of breast cancer, a causal association between inflammation and the formation of malignant tumors has not been adequately established [3]. These instances demonstrate that persistent granulomatous mastitis may serve as a prelude to cancer [7]. Indeed, oxidative stress has been related to the onset and development of cancer by raising DNA mutations or generating DNA damage, genomic instability, and cell proliferation [5]. One mechanism by which persistent inflammation may trigger cancer is the formation of Reactive Nitrogen and Oxygen Species (RNS and ROS) in the inflamed tissue, followed by DNA damage that activated oncogenes and/or inactivated tumor suppressor genes [6]. There is hope that chemoprevention or chemotherapy can be achieved through targeting the specific components of particular inflammation signaling molecules. However, given our current understanding of persistent inflammatory states of tumor microenvironment, tumor cell-host stroma communication, and the effect of inflammation signaling molecules on oncogenesis, it is unlikely that this will be possible [6]. The uncommon occurrence of IGM and DCIS in the same breast highlights the necessity of biopsy in the diagnosis, therapy, and follow-up of individuals with this unusual relationship. Radiologists, pathologists, and breast surgeons are all challenged by this very unusual disorder [3]. In conclusion, three alternative possibilities are feasible in our patients. First, the patients had

breast cancer that was misdiagnosed as granulomatous mastitis throughout the period, although pathological diagnoses were subjected to a second opinion. Second, patients had the misfortune of developing breast cancer as a secondary disease in the same breast. Third, patients acquired breast cancer as a consequence of prolonged inflammation, which caused dysplasia and then malignancy [7]. However, the time it takes for inflammation to turn into malignancy should be discussed. Whether or not our patients got cancer as a result of idiopathic granulomatous mastitis is debatable until more cases are seen and more study is conducted in the field of breast cancer etiology as it relates to idiopathic granulomatous mastitis.

Declarations

Ethical approval: Not applicable.

Data availability statement: The data that support the findings of this study are available from the Cancer Research Centre of Shahid Beheshti University of Medical Sciences. Restrictions apply to the availability of these data, which were used under license for this study. Data are available from the authors upon reasonable request and with the permission of Shahid Beheshti University of Medical Sciences.

Conflict of interest: The authors have no conflicts of interest to declare.

Funding sources: This research was funded by Shahid Beheshti University of Medical Sciences. The university played no role in the study design, data collection and analysis, decision to publish, or preparation of the manuscript.

References

1. Özşen MŞ, Tolunay MŞ, Gökğöz. Case Report: Ductal Carcinoma in Situ Within A Granulomatous Mastitis. *European journal of breast health*. 2018; 14: 186-188.
2. Halim NA, et al. Idiopathic Granulomatous Mastitis Presenting as a Breast Pseudotumor: Case Reports with Review of the Literature. *Case Reports in Rheumatology*. 2018; 2018: 4264012.
3. Oddó D, et al. Granulomatous lobular mastitis associated with ductal carcinoma in situ of the breast. *SAGE open medical case reports*. 2019; 7: 2050313X19836583.
4. Halim NA, et al. Idiopathic granulomatous mastitis presenting as a breast pseudotumor: Case reports with review of the literature. *Case reports in rheumatology*. 2018; 2018.
5. Reuter S, et al. Oxidative stress, inflammation, and cancer: how are they linked? *Free radical biology and medicine*. 2010; 49:

6. Kundu JK, YJ, Surh. Inflammation: Gearing the journey to cancer. Mutation Research/Reviews in Mutation Research. 2008; 659: 15-30.
7. Luqman M, et al. Breast carcinoma occurring from chronic granulomatous mastitis. The Malaysian journal of medical sciences: MJMS. 2012; 19: 82.
8. Kaviani AZS, Karbaksh M, Azmoudeh Ardalan F. Synchronous Idiopathic Granulomatosis Mastitis and Breast Cancer: A Case Report and Review of Literature. Arch Breast Cancer. 2017; 4: 32-36.