

## Clinical Image

Open Access, Volume 5

# Bleeding arterioles in a case of silent abruption

Snigdha Kumari; Abhay Kumar\*

Department of Obstetrics and Gynecology, PGIMER, Chandigarh, India.

\*Corresponding Author: **Abhay kumar**

Department of Obstetrics and Gynecology, PGIMER,  
Chandigarh, India.

Email: abhay3090@gmail.com

Received: Apr 12, 2024

Accepted: Apr 26, 2024

Published: May 03, 2024

Archived: www.jcimcr.org

Copyright: © Kumar A (2024).

DOI: www.doi.org/10.52768/2766-7820/3028

### Description

A 24-year-old female at 28 weeks period of gestation referred to our emergency with history of preeclampsia and increased umbilical artery pulsatility index with no history of bleeding per vaginum was detected with partial separation of placenta (asterisk) and bleeding spiral arterioles (arrow) (Figure 1) with a single live fetus of 900 gms on ultrasonography. On examination, her vitals were stable, uterus corresponded to 28 weeks, non-tender, relaxed and fetal heart was present. Subsequent monitoring revealed increased area of separation and patient underwent emergency cesarean in anticipation of complete separation of placenta. Intraoperatively, the placenta was completely separated, and bleeders were secured.

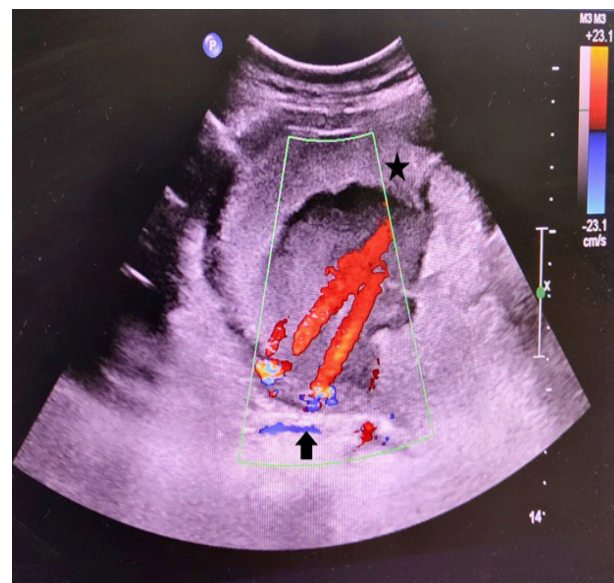


Figure 1: Clinical image.