

Clinical Image*Open Access, Volume 5***A rare case of ethmoidal encephalocele with corpus callosal dysgenesis****Nayan Kabra^{1*}; Atish Komwad²; Balaji Kombade³**¹Junior Resident, VDGMC, Latur, India.²Associate Professor, VDGMC, Latur, India.³Professor and HOD, VDGMC, Latur, India.***Corresponding Author: Nayan Kabra**

Junior Resident, VDGMC, Latur, India.

Email: nankabra26@gmail.com

Received: Jun 10, 2024

Accepted: Jun 25, 2024

Published: Jul 02, 2024

Archived: www.jcimcr.org

Copyright: © Kabra N (2024).

DOI: www.doi.org/10.52768/2766-7820/3148

Description

A 6 mm defect is seen over anterior aspect of face in between both orbits with a 2.6 x 2.5 cm sized cystic collection herniating through the defect possibly arising from ethmoid s/o Ethmoidal encephalocele. CSP (Cavum Septum Pellucidum) is not well visualised with bilateral parallel orientation of lateral ventricles. Third ventricle appears dilated. Splenium of corpus callosum not well visualised s/o Dysgenesis of corpus callosum. Cerebral hemispheres and Posterior fossa structure appears normal. A 6 mm defect is seen over anterior aspect of face in between both orbits with a 2.6 x 2.5 cm sized cystic collection herniating through the defect possibly arising from ethmoid s/o Ethmoidal encephalocele.

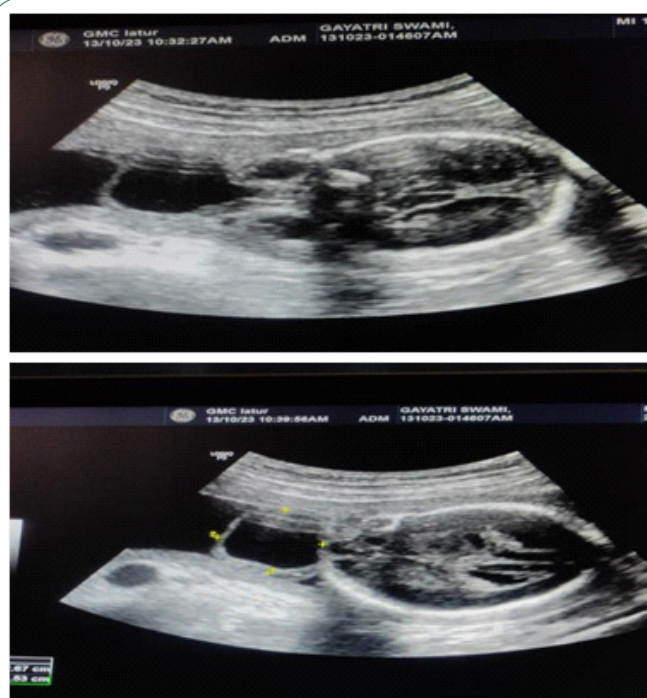


Figure 1: A 6 mm defect is seen over anterior aspect of face in between both orbits with a 2.6 x 2.5 cm sized cystic collection herniating through the defect possibly arising from ethmoid s/o Ethmoidal encephalocele.

Citation: Kabra N, Komwad A, Kombade B. A rare case of ethmoidal encephalocele with corpus callosal dysgenesis. J Clin Images Med Case Rep. 2024; 5(7): 3148.

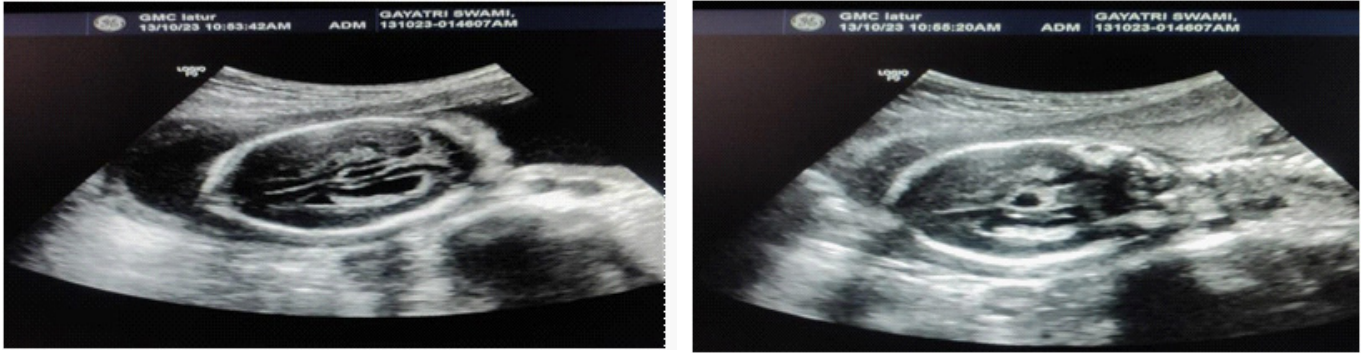


Figure 1: CSP (Cavum Septum Pellucidum) is not well visualised with bilateral parallel orientation of lateral ventricles. Third ventricle appears dilated. Splenium of corpus callosum not well visualised s/o Dysgenesis of corpus callosum. Cerebral hemispheres and Posterior fossa structure appears normal.