

Clinical Image

Open Access, Volume 5

Pseudopolyposis ulcerative colitis: An unusual finding

Derqaoui Sabrine^{1,3*}; Bakali Youness^{2,3}

¹Department of Pathology, Ibn Sina Teaching Hospital, Rabat, Morocco.

²Department of Surgery C, Ibn Sina Teaching Hospital, Rabat, Morocco.

³Faculty of Medicine, Mohamed V University, Rabat, Morocco.

*Corresponding Author: **Derqaoui Sabrine**

Department of Pathology, Ibn Sina Teaching Hospital, Rabat, Morocco.

Tel: 212537676464 & 2125377758;

Email: s.derqaoui@gmail.com

Received: Jun 22, 2024

Accepted: Jul 11, 2024

Published: Jul 18, 2024

Archived: www.jcimcr.org

Copyright: © Sabrine D (2024).

DOI: www.doi.org/10.52768/2766-7820/3175

Description

Diffuse inflammatory polyposis of the colon is a rare finding in Inflammatory Bowel Disease (IBD). Herein we describe a unique case of diffuse giant inflammatory polyposis in a 39-year-old women, admitted to the department of surgery for undetermined pancolitis without history of IBD. Gross examination revealed diffuse giant polyps ranging from 0,5 to 2 cm sparing the ceacum (Figure 1A). Extensive sampling was performed to rule out malignancy. Histology showed inflammatory polyps with marked acute inflammation and hyperplastic cystically dilated glands (Figures 1B and C).

Declarations

Competing interests: The authors declare that they have no competing interests.

Consent: Informed consent was obtained from the patient's guarantor.

Authors' contributions: All authors read and approved the final manuscript.

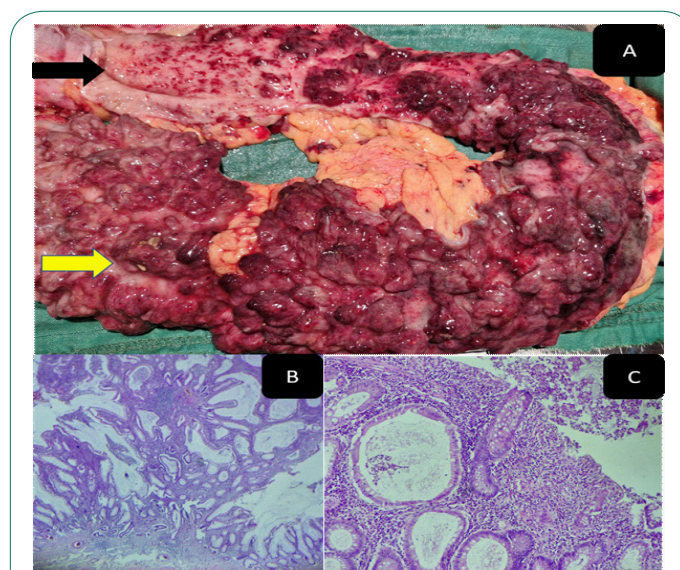


Figure 1: Clinical image.

Citation: Sabrine D, Youness B. Pseudopolyposis ulcerative colitis: An unusual finding. J Clin Images Med Case Rep. 2024; 5(7): 3175.