

**Clinical Image**

Open Access, Volume 5

## A long foreign body swallowed and spontaneously defecated in a child

\*Corresponding Author: **Mohammad Ali Mahdiabadi**

Department of Internal Medicine, School of Medicine,  
Birjand University of Medical Sciences, Birjand, Iran.

Email: mahdiabadi\_ma@yahoo.com

Received: Jul 10, 2024

Accepted: Jul 25, 2024

Published: Aug 01, 2024

Archived: www.jcimcr.org

Copyright: © Mahdiabadi MA (2024).

DOI: www.doi.org/10.52768/2766-7820/3188

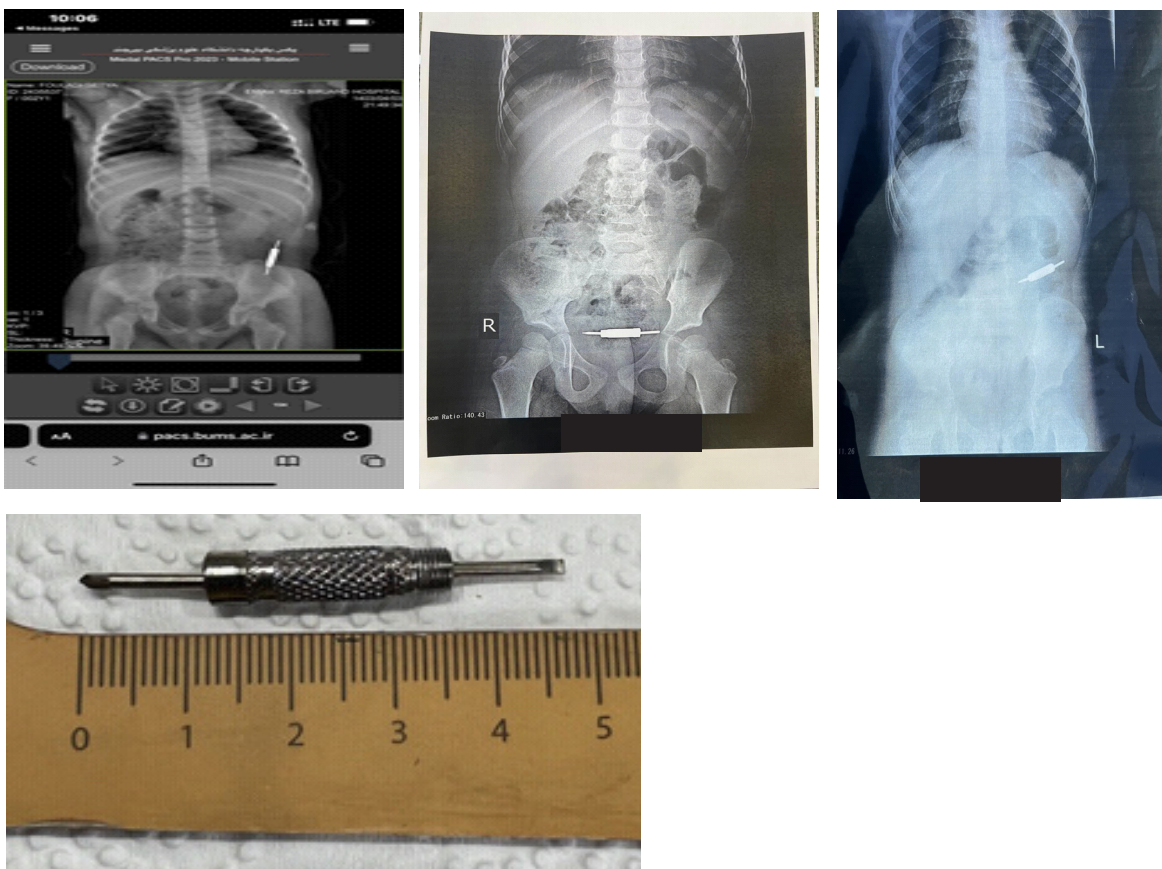


Figure 1: Clinical images.

### Description

A 33-month-old girl without any underlying diseases accidentally swallowed a small screwdriver. She had initially symptoms like coughing and suffocation, which improved within a few minutes. After a few hours, when they went to the hospital and an X-ray was taken, they learnt about its presence in the patient's body. Considering that the child did not have significant clinical symptoms and there was no abnormality in the examination she was monitored at home and followed up with serial radiographs. After about 67 hours, the above-mentioned foreign body was defecated along with the patient's feces and the patient did not have any symptoms thereafter.