

**Case Report**

Open Access, Volume 5

## May-Thurner syndrome: Silent cause of venous thromboembolism

Sofia Eusébio<sup>1\*</sup>; Joana Cardoso<sup>2</sup>; Afonso Rodrigues<sup>1</sup>

<sup>1</sup>Unidade Funcional de Medicina 4, Unidade local de saúde de São José, Lisboa, Portugal.

<sup>2</sup>Serviço de Cirurgia Vascular, Unidade local de saúde de São José, Lisboa, Portugal.

**\*Corresponding Author: Sofia Eusébio**

Unidade Funcional de Medicina 4, Unidade local de saúde de São José, Lisboa, Portugal.

Tel: +351912668634;

Email: sofia.peusebio@gmail.com

Received: Nov 12, 2024

Accepted: Nov 28, 2024

Published: Dec 05, 2024

Archived: www.jcimcr.org

Copyright: © Eusébio S (2024).

DOI: www.doi.org/10.52768/2766-7820/3374

### Description

May-Thurner Syndrome (MTS) is characterized by the compression of the left iliac vein when it passes between the right common iliac artery and the spine. Complications of MTS include deep vein thrombus formation and even life-threatening pulmonary embolism. The authors present a case of 33-year-old female with thromboembolism and imagiological findings of MTS. The authors want to enhance the importance of awareness of MTS on patients with unexplained lower limb swelling.

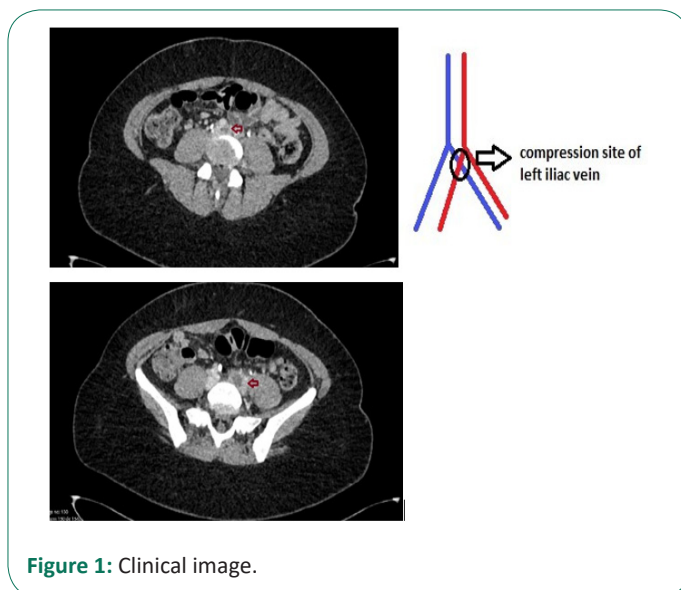


Figure 1: Clinical image.

**Citation:** Eusébio S, Cardoso J, Rodrigues A. May-Thurner syndrome: Silent cause of venous thromboembolism. J Clin Images Med Case Rep. 2024; 5(12): 3374.